

# INTACS Inserts Using the Femtosecond Laser Compared to the Mechanical Spreader in the Treatment of Keratoconus

Yaron S. Rabinowitz, MD; Xiaohui Li, MD; Teresa S. Ignacio, MD; Ezra Maguen, MD

## ABSTRACT

**PURPOSE:** To determine the efficacy of INTACS insertion using a femtosecond laser in the treatment of keratoconus and to compare it to the technique using a mechanical spreader.

**METHODS:** INTACS were inserted in 10 eyes using the mechanical spreader to create the channels and subsequently on another 20 eyes using the femtosecond laser. Uncorrected (UCVA) and best spectacle-corrected visual acuity (BSCVA), manifest refraction, and corneal topography were measured prior to surgery, at 6 months (femtosecond group), and 1 year (mechanical group). Pre- and postoperative data were analyzed to determine changes in the above parameters.

**RESULTS:** Both groups showed significant reduction in average keratometry (K), spherical equivalent refraction, BSCVA, UCVA, surface regularity index (SRI), and surface asymmetry index (SAI). The laser group performed better in all parameters except change in SRI. Results of the laser versus the mechanical spreader were as follows: reduction in spherical equivalent refraction (3.98 vs 2.96), change in average K (2.91 vs 2.52), improvement in UCVA (4.13 vs 3.63), improvement in BSCVA (3.92 vs 1.63), change in SRI (0.37 vs 0.64), and change in SAI (1.00 vs 0.70). Statistical analysis, however, did not reveal any statistically significant differences between the two groups for any single parameter studied. The biggest improvement in the laser group versus the mechanical group was BSCVA ( $P=.09$ ). Overall success, defined as contact lens or spectacles tolerance, was 85% in the laser group and 70% in the mechanical group.

**CONCLUSIONS:** Inserting INTACS using the femtosecond laser to create the channels is as effective as using the mechanical spreader. [*J Refract Surg.* 2006;22:764-771.]

**K**eratoconus is an ectatic corneal disorder with an incidence of approximately 1 in 2000.<sup>1</sup> The mainstay of treatment is rigid contact lenses, which provide a smooth anterior surface that neutralizes the myopia and irregular astigmatism associated with this disorder.<sup>2</sup> When these patients become contact lens-intolerant, even in the absence of central scarring, they are faced with the need for a corneal transplant, as spectacles cannot provide adequate functional vision.<sup>3</sup>

INTACS (KeraVision, Fremont, Calif) are small arc-like polymethylmethacrylate segments approved for the correction of low myopia in 1990.<sup>4</sup> In 2001, Joseph Colin, MD, first proposed INTACS use in patients with keratoconus who are contact lens-intolerant with a clear visual axis to prevent or delay the need for a corneal transplant.<sup>5</sup> He reported 1-year results on 10 patients and demonstrated improved corrected and uncorrected visual acuity and return to contact lens-tolerance in all patients.<sup>6</sup> Since his publication, several investigators have reported similar results using a mechanical spreader provided by the manufacturer to insert the INTACS.<sup>7-11</sup>

Recently, a femtosecond laser (IntraLase Corp, Irvine, Calif) received Food and Drug Administration approval in the United States.<sup>12</sup> This laser has the unique capability of programming channels at a predetermined depth with a high de-

---

*From the Cornea Genetic Eye Institute, Cedars-Sinai Medical Center, Los Angeles (Rabinowitz, Li, Maguen), and the Department of Ophthalmology, University of California, Irvine (Ignacio), Calif.*

*Supported in part by the Eye Birth Defects Research Foundation Inc and NEI grant #09052.*

*Dr Ignacio is a consultant to IntraLase Corp. The remaining authors have no financial or proprietary interest in the materials presented herein.*

*Presented as part of "The Keynote Lecture entitled 'Keratocone: Concepts actuels'" at the French Eye Society, May 9, 2005, Paris, France; and ISRS/AO Refractive Surgery Subspecialty Day, October 14, 2005, Chicago, Ill.*

*Correspondence: Yaron S. Rabinowitz, MD, Cornea Genetic Eye Institute, Cedars-Sinai Medical Center, 444 S San Vicente Blvd, #1102, Los Angeles, CA 90048. Tel: 310.423.9640; Fax: 310.423.9649; E-mail: rabinowitz@cshs.org*

*Received: November 11, 2005*

*Accepted: April 4, 2006*

*Posted online: July 31, 2006*

gree of accuracy for inserting INTACS, thus potentially dispensing with the need for the mechanical spreader provided by the manufacturer. We performed a retrospective analysis on data derived from patients seen in our office to compare the accuracy and the efficacy of this new femtosecond laser for inserting INTACS compared to results achieved using the mechanical spreader provided by the manufacturer.

## PATIENTS AND METHODS

### PATIENT RECRUITMENT AND EVALUATION

This study comprised 24 consecutive patients (30 eyes) with keratoconus who were contact lens-intolerant with a clear visual axis who were referred for corneal transplant and were considering INTACS as a therapeutic alternative. To qualify for enrollment in the study, patients had to have a mesopic pupil size of  $<6.5$  mm and corneal thickness at the 7-mm optical zone of  $>450$   $\mu\text{m}$ . In addition to pupil size and corneal thickness, the following parameters were measured in all patients preoperatively and at 6 months postoperatively: uncorrected visual acuity (UCVA), best spectacle-corrected visual acuity (BSCVA), corneal thickness, keratometry readings (K), and computer-assisted videokeratography.

### SURGICAL TECHNIQUE

*Mechanical Technique.* The first 8 patients (10 eyes) underwent INTACS insertion using a standard technique with a mechanical spreader to make the channels as described by Colin et al.<sup>5,6</sup> In all patients studied, symmetric segments were used with a 0.35-mm INTACS segment placed superiorly and a 0.35-mm INTACS segment placed inferiorly. In all patients, a 10-0 nylon suture was used to close the entry wound; this suture was placed at 100% depth and removed 1 month after surgery.

*Femtosecond Laser (IntraLase) Assisted Technique.* The following technique was used on the next 20 eyes of 16 patients who had surgery using the IntraLase to make the channels for inserting the INTACS. A drop of tetracaine was applied to the eye. The center of the pupil was marked using a felt tipped pen. The suction ring was lowered onto the cornea and centered on the point previously marked to show the preoperative position of the center of the pupil. The following laser settings were used on all patients who underwent data analysis: channel depth 400  $\mu\text{m}$ , entry incision length 1.4 mm, entry incision width 1 mm, channel size inner diameter 6.6 mm, and outer diameter 7.4 mm. This effectively creates a 0.4-mm channel size, which is 0.05 mm larger than the size of the INTACS. The op-

timum channel size was determined by trial and error using several adjacent parameters. Initial cases were performed with an 8.0-mm outer diameter, then a 7.6-mm diameter with little effect, and ultimately, an outer diameter of 7.4 mm, which demonstrated maximal effect. It became evident that the narrower the channels, the more effect; however, a narrower channel also results in increased difficulty in inserting the INTACS. The 6.6 $\times$ 7.4-mm setting was the best compromise between maximal outcome and ease of INTACS insertion.

The entry wound and channel creation takes 12 seconds. Once completed, the suction ring is removed and the patient is moved to an operating microscope. The cornea is hydrated with a balanced saline solution and the entry wound is opened with a Sinsky hook (Medicon, Denmark). The channels are also inspected for patency by inserting the Sinsky hook into the channels. The Sinsky hook is then used to elevate the entry lip of the circular channel and the inferior INTACS segment is placed beneath the Sinsky hook and carefully pushed forward with the INTACS holder until the edge of the INTACS has been advanced to 1 mm from the entry wound. A similar maneuver is performed for inserting the superior INTACS segment. The incision entry is closed with a single 10-0 nylon suture placed at 100% corneal depth and sutured tight. A bandage contact lens was applied for the first postoperative day only. Postoperative topical medications given were prednisolone acetate 1% (Pred Forte; Alcon Laboratories, Ft Worth, Tex) every hour, ketorolac tromethamine 0.5% (Acular; Allergan, Irvine, Calif), and gatifloxacin 0.3% (Zymar, Allergan) four times daily for the first day and tapered as necessary over 1 week.

In 15 eyes, two symmetrical 0.35-mm segments were inserted, as the overall goal was to flatten the cornea enough to make patients, who were contact lens-intolerant, contact lens-tolerant. In four eyes with milder disease, a single 0.35-mm segment was inserted inferiorly only. In one eye, a 0.25-mm segment was inserted superiorly and a 0.35-mm segment was inserted inferiorly. The decision to put in a single segment was based on the fact that these patients had mild inferior cones only, which could potentially be adequately corrected using a single segment. The decision to use asymmetric segments in one eye was made to reduce the astigmatism in the eye.

### DATA ANALYSIS

A retrospective chart review was performed of 24 keratoconus patients (30 eyes) who underwent placement of INTACS by the same surgeon (Y.S.R.), 10 eyes with the mechanical spreader and 20 eyes with the

TABLE 1

**Comparison of Outcome Data (Mean  $\pm$  Standard Deviation) in Eyes That Underwent INTACS Insertion for Keratoconus—IntraLase Group (6 Months) Versus the Mechanical Group (12 Months) (Present Study)**

Parameter	IntraLase (n=15)	Mechanical (n=10)	P Value*
Age (y)	39.5 $\pm$ 13.5	38.3 $\pm$ 8.2	.63
Spherical equivalent refraction†	3.98 $\pm$ 3.02	2.96 $\pm$ 2.74	.26
Keratometry†	2.91 $\pm$ 2.45	2.52 $\pm$ 2.21	.83
UCVA†	4.13 $\pm$ 3.02	3.63 $\pm$ 2.67	.70
BSCVA†	3.92 $\pm$ 2.40	1.63 $\pm$ 3.58	.09
SRI†	0.37 $\pm$ 0.34	0.64 $\pm$ 0.54	.16
SAI†	1.00 $\pm$ 1.19	0.70 $\pm$ 0.65	.90
Contact lens tolerant† ‡	17/20§	7/10	.37

UCVA = uncorrected visual acuity, BSCVA = best spectacle-corrected visual acuity, SRI = surface regularity index, SAI = surface asymmetry index

\*t test used for data with normal distribution, Wilcoxon test used for data without normal distribution.

†Values represent change in parameter.

‡Fisher exact test.

§To make the comparison valid, only eyes with two INTACS segments placed in each eye were compared to each other (ie, 15 IntraLase patients had two segments inserted; however, another 5 had a single segment inserted for a total of 20 eyes studied).

femtosecond laser, performed between March 26, 2003 and August 10, 2004. Data comparisons and analysis between the two groups were done for age, change in UCVA, BSCVA, K readings, spherical equivalent refraction, surface regularity index (SRI), and surface asymmetry index (SAI) on the Tomey topography system (Tomey, Nagoya, Japan). The two groups were also compared for successful outcomes defined as contact lens–tolerance with adequate acuity following surgery. The femtosecond group was compared for outcomes not only with the present mechanical study but also for two other studies using a mechanical spreader reported in the ophthalmic literature.<sup>6,7</sup> Analysis of a subgroup of four patients in the femtosecond group who had a single segment inserted inferiorly versus the main group of 15 who had two symmetric 0.35-mm segments inserted was also performed.

### RESULTS

Eight patients (10 eyes) with keratoconus, 7 men (87%) and 1 woman (13%), with a mean age of 38.3 $\pm$ 8.2 years (range: 26 to 51 years) underwent mechanical placement of INTACS. Sixteen patients (20 eyes) with keratoconus, 11 men (69%) and 5 women (31%), with a mean age of 39.5 $\pm$ 13.5 years (range: 21 to 63 years) underwent femtosecond laser placement of INTACS. Statistical analysis revealed no statistically significant differences for age ( $P=.63$ ) (Table 1).

### MECHANICAL GROUP

A summary of the results for this group, including the mean and range for each parameter, is presented in Table 1. With regard to the overall goal of the study, which was to achieve contact lens or spectacles tolerance in keratoconus patients, 7 (70%) of 10 achieved this goal at 1 year.

In one patient, the INTACS extruded because it was placed too superficially and the patient elected not to have it reinserted. In a second patient, although he experienced good results in both eyes, he complained of continued fluctuation of vision persisting up to 1 year postoperatively and elected to have a penetrating keratoplasty in both eyes.

The mechanical procedure took an average of 25 to 30 minutes to perform, and 50% of patients had significant epithelial defects on the first postoperative day along with moderate to severe discomfort.

### FEMTOSECOND LASER GROUP

A summary of the results for this group, including the mean $\pm$ standard deviation for each parameter, is presented in Table 1. With regard to the overall goal of the study, which was to achieve contact lens or spectacles tolerance in keratoconus patients, 17 (85%) of 20 eyes achieved this goal at 6 months. In one patient, whose stitch became loose on the second postoperative day and who refused to allow the surgeon to put in a replacement stitch, a gram-positive infection developed. The wound site appeared to be the site of

TABLE 2

**IntraLase Results at 6 Months Compared to Mechanical Spreader Results at 1 Year by Colin et al<sup>6</sup>**

Parameter	IntraLase (Mean ± SD) (n=15)	Mechanical (Mean) (n=10)
Keratometry* (D)	2.91±2.45	4.6†
SEQ* (D)	3.98±3.02	N/A
UCVA* (lines)	4.13±3.02†	3
BSCVA* (lines)	3.92±2.4†	2.0
Segment size* (mm)	0.35	0.25 and 0.45

SD = standard deviation, SEQ = spherical equivalent refraction, N/A = not available, UCVA = uncorrected visual acuity, BSCVA = best spectacle-corrected visual acuity  
 \*Values represent change in parameter.  
 †Better result.

TABLE 3

**IntraLase Results at 6 Months Compared to Mechanical Spreader Results at 1 Year by Siganos et al<sup>7</sup>**

Parameter	IntraLase (Mean ± SD) (n=15)	Mechanical (Mean) (n=33)
Keratometry* (D)	2.91±2.45	1.94
SEQ* (D)	3.98±3.02	1.82
UCVA* (lines)	4.13±3.02†	2.5
BSCVA* (lines)	3.92±2.4†	1.7
Segment size* (mm)	0.35	0.45

SD = standard deviation, SEQ = spherical equivalent refraction, UCVA = uncorrected visual acuity, BSCVA = best spectacle-corrected visual acuity  
 \*Values represent change in parameter.  
 †Better result.

TABLE 4

**Comparison of Data for the Single INTACS Group vs Two INTACS (0.35 mm)**

Parameter	Single INTACS (n=5)	Two INTACS (n=15)	P Value*
SEQ† (D)	1.71±1.78	3.98±3.02	.25
Keratometry† (D)	1.06±0.69	2.91±2.45	.29
UCVA†	3.25±2.99	4.13±3.02	.65
BSCVA†	3.50±3.11	3.92±2.40	.78
SRI†	0.31±0.25	0.37±0.34	.75
SAI†	0.56±0.62	1.00±1.19	.87
Contact lens tolerant† ‡	5/5	12/15	.53

SEQ = spherical equivalent refraction, UCVA = uncorrected visual acuity, BSCVA = best spectacle-corrected visual acuity, SRI = surface regularity index, SAI = surface asymmetry index  
 \*t test used for data with normal distribution, Wilcoxon test used for data without normal distribution.  
 †Values represent change in parameter.  
 ‡Fisher exact test.

entry. At the time of infection, the wound was gaping and both segment edges were close to each other under the wound. It appears that the patient rubbed his eye, which contributed to the movement of the segment and subsequent wound gap and resultant infection. The INTACS was removed and the infection was brought under control with intensive fortified antibiotics. In two patients, the cone was too advanced even after INTACS placement and the patients were not able to tolerate rigid or soft toric contact lenses. Both of these patients opted for subsequent penetrating keratoplasty and did well with the removal of the INTACS at the time of keratoplasty.

The procedure with the femtosecond laser took an average of 10 to 15 minutes. (It takes 12 seconds to create both the vertical and circular channels once the laser cone is applied to the cornea.) Only three (15%) patients had significant epithelial defects and experienced moderate to severe discomfort on the first post-operative day.

**COMPARISON OF GROUPS**

Comparative data for the femtosecond laser and mechanical data groups for this study are summarized in Table 1. Table 2 summarizes the comparison of the femtosecond laser group in this study to the group



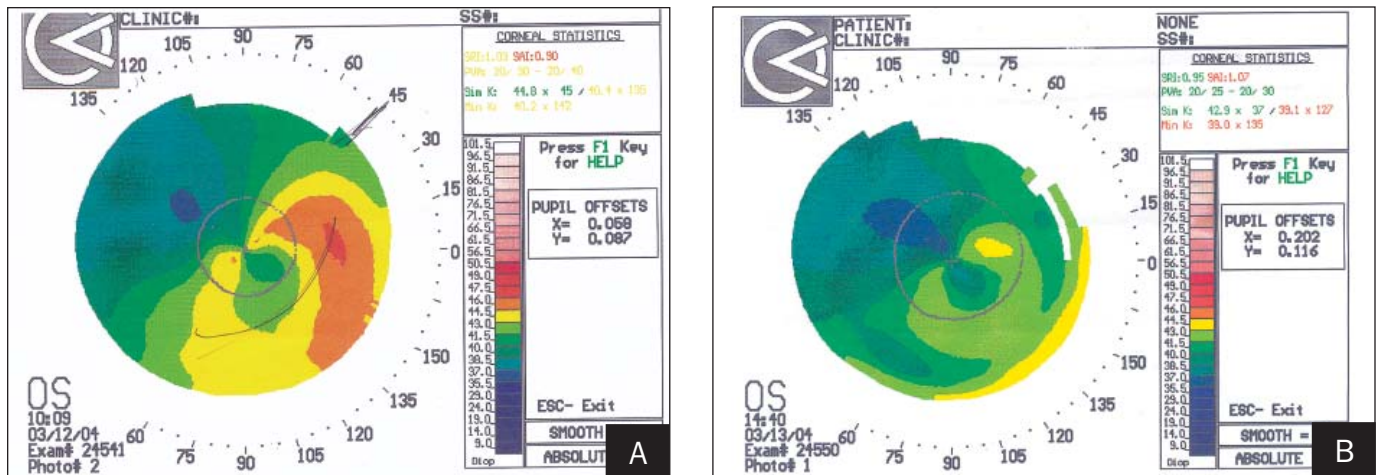


Figure 1. Case 1. A) Pre- and B) postoperative corneal topographies. Flattening at the site of INTACS insertion can be seen.

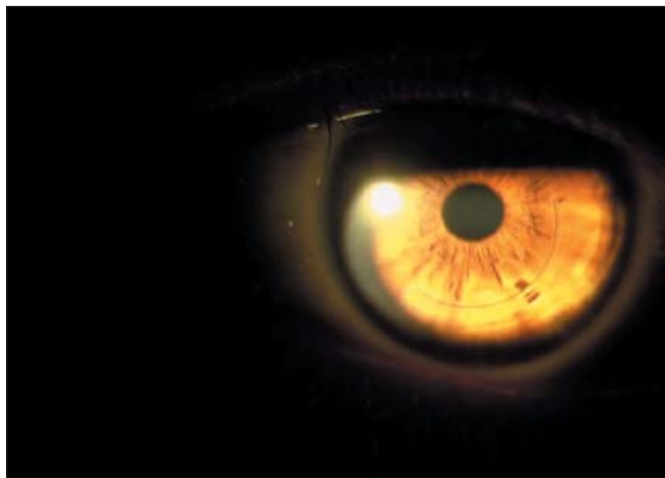


Figure 2. Case 1. Slit-lamp photograph on postoperative day 1 showing location of INTACS.

studied by Colin et al.<sup>6</sup> It should be noted that Colin et al used 2.5- and 4.5-mm thick segments (which are not available for use in the United States). Comparison of the present study femtosecond laser data and those of a mechanical study of a cohort of patients who had INTACS performed by Siganos et al<sup>7</sup> with the mechanical method are summarized in Table 3. (This group used two 4.5-mm segments.) Analysis of the femtosecond laser group in the present study was performed to compare the outcome of a single INTACS placement versus placing two INTACS, and these results are presented in Table 4.

**CASE REPORTS**

The following two case reports illustrate the potential for INTACS for correcting both UCVA and BSCVA in patients with mild to moderate keratoconus using the femtosecond laser.

**CASE 1**

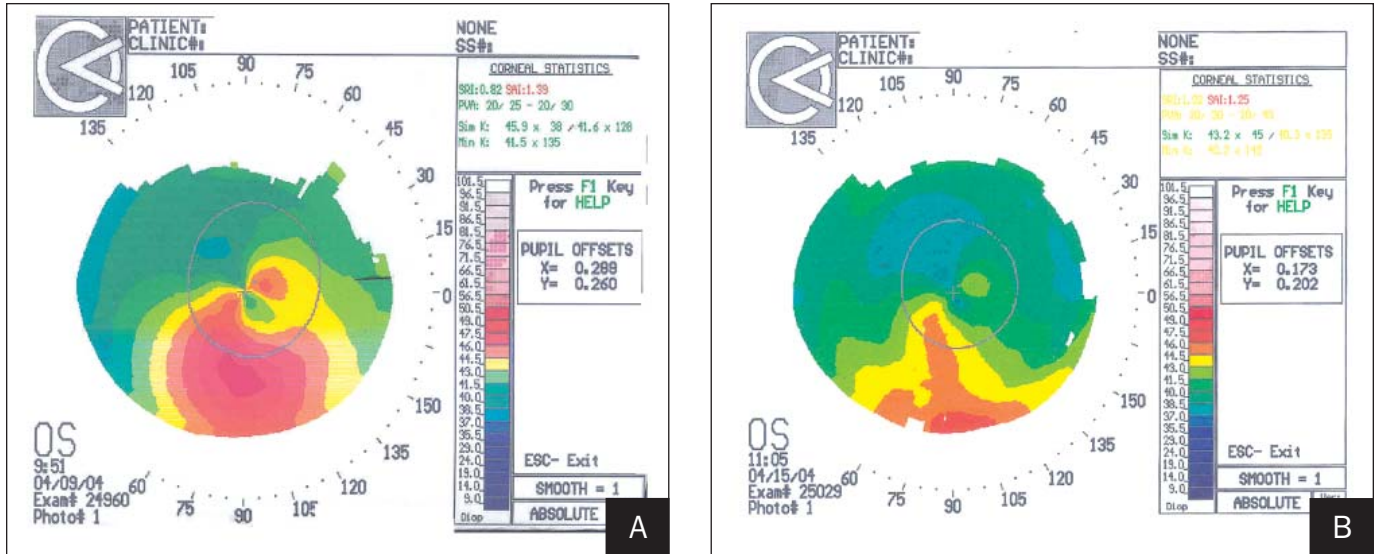
A 40-year-old man with mild keratoconus, whose BSCVA was 20/70, did not want to wear contact lenses but wanted an improvement in BSCVA. Preoperative manifest refraction was plano  $-3.00 \times 70^\circ$ .

Videokeratography revealed a mild inferotemporal cone (Fig 1A). A single 0.35-mm INTACS was inserted to ensure the arc of the segment bisected the thinnest part of the cornea. On postoperative day 1, BSCVA was 20/20 and this vision was maintained for 1 year. Refraction was  $+1.00 -1.00 \times 90^\circ$ . Corneal topography demonstrated significant flattening in the area of the INTACS insertion (Fig 1B). His eye was quiet on postoperative day 1 with excellent wound healing (Fig 2).

**CASE 2**

A 35-year-old woman with mild keratoconus was rigid contact lens-intolerant. Best spectacle-corrected visual acuity was 20/70 with a  $+1.50 -3.00 \times 60^\circ$  refraction. A mild inferotemporal cone was seen on videokeratography (Fig 3A).

A temporal incision was performed, and asymmetric INTACS, 0.25 mm above and 0.35 mm below, were inserted. On postoperative day 1, UCVA was 20/20 with a  $+3.50$  refraction. Videokeratography demonstrated significant asymmetric flattening (Fig 3B), and the eye was quiet with no discomfort on the first postoperative visit (Fig 4). The patient wears a  $+3.50$  diopter (D) disposable contact lens, which she has been wearing for the past year. At 1-year follow-up, her refraction remains unchanged and she is still tolerant of soft contact lenses with excellent acuity in the eye. Wavefront analysis with the Alcon LADARWave aberrometer (Alcon Laboratories) preoperatively demonstrated a total root mean square (RMS) of 2.39 and vertical coma of 2.60 (Fig 5A). Postoperatively, total RMS was reduced to 1.39



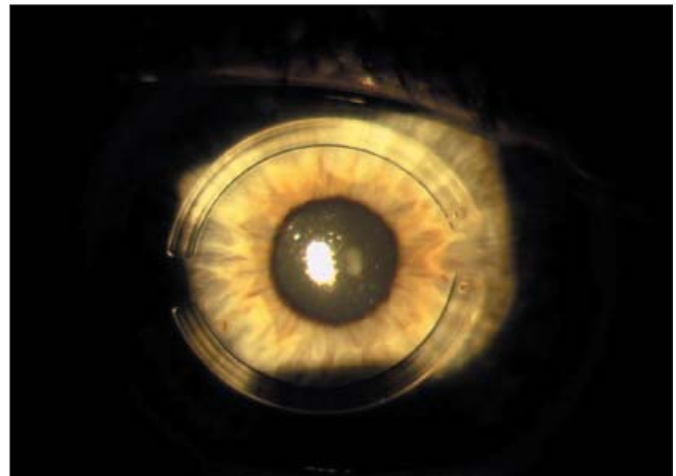
**Figure 3.** Case 2. **A)** Pre- and **B)** postoperative corneal topographies. Postoperative topography demonstrates significant flattening in the area of insertion of the INTACS inferiorly with a reduction of astigmatism as illustrated by the SimK value.

and coma to 1.80 (Fig 5B). Improvement in UCVA and BSCVA are explained by the >50% reduction in astigmatism, vertical coma, and total RMS (Table 5).

**DISCUSSION**

Our study, along with previously published studies, confirms the findings that INTACS in the treatment of keratoconus are effective in flattening the cornea and thereby improving both the UCVA and BSCVA in these patients. It also demonstrates what has been previously reported, that although this treatment is effective in the majority of patients, the results are variable. INTACS can improve BSCVA as much as 10 lines, but rarely reduces BSCVA as much as 2 lines—overall there is an average 3.0-D flattening effect similar to that found in the FDA study using 0.35-mm INTACS segments for treating spherical myopia.<sup>13</sup>

In the mechanical group, our results were similar to those reported by Colin et al<sup>6</sup> and Siganos et al.<sup>7</sup> Seven (70%) of 10 eyes in this group achieved the goal of becoming contact lens-tolerant with acceptable contact lens corrected visual acuity. In the femtosecond laser group, the results at 6 months were better overall than the mechanical group in the visual outcome measures. Uncorrected visual acuity and BSCVA were better by 2 lines in the laser group versus the mechanical group in our study (Table 1) and >2 lines better than the data from three combined mechanical studies at 1 year (present study, Colin et al,<sup>6</sup> and Siganos et al<sup>7</sup>) (Tables 2 and 3). The differences between the two groups were not statistically significant. Seventeen (85%) of 20 eyes attained contact lens-tolerance or improved best cor-



**Figure 4.** Case 2. Digital slit-lamp photograph 1 day postoperatively shows asymmetric INTACS segments placement.

rected visual acuity with spectacles or contact lenses.

Because our group was among the first to use and report results on this device for implanting INTACS into the cornea, no nomogram had been developed to determine the optimal settings for the circular channel for INTACS insertion. The company originally recommended an inner diameter of 6.6 mm and an outer diameter of 8.0 mm. We noticed that in the initial cases, although the INTACS were inserted with little difficulty, we experienced minimal effect from the surgery. Over time we realized that as we made the channels narrower we achieved more of an effect. Ultimately, we settled for a 6.6-mm inner diameter and a 7.4-mm outer diameter, which were the parameters used for most of the patients in this study. As can be seen from this

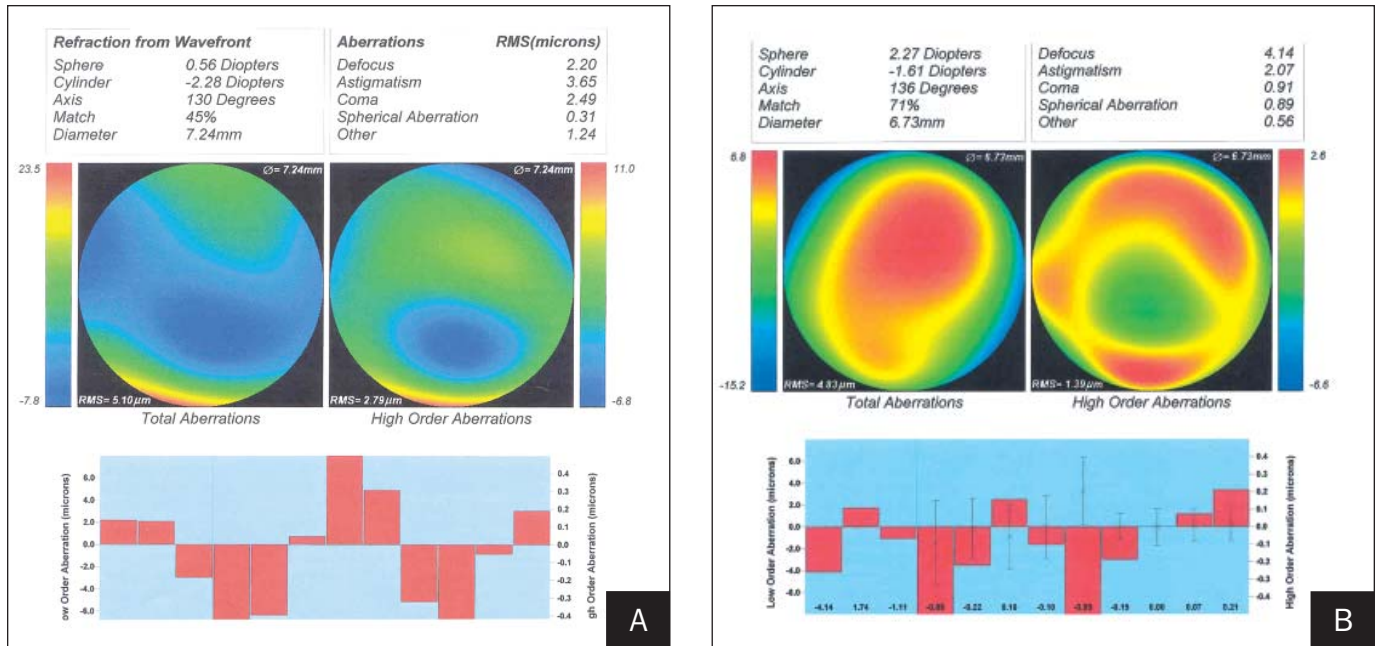


Figure 5. Case 2. A) Pre- and B) postoperative Alcon LADARWave wavefront maps. The postoperative map demonstrates a significant decrease in coma and root mean square.

TABLE 5

**Improvement in Wavefront Data (Case 2)**

	Preop	Postop	% Change
Refractive astigmatism (D)	3.65	2.07	<43
Spherical aberration ( $\mu\text{m}$ )	0.31	0.89	>187
Coma ( $\mu\text{m}$ )	2.49	0.91	<63
Total RMS ( $\mu\text{m}$ )	2.79	1.29	<53

RMS = root mean square

study, good results can be achieved using these parameters and the INTACS can be inserted relatively easily with these settings. We noted that we can achieve a greater effect by making the channels even narrower; however, this significantly increases surgical time and may result in more patient discomfort. This is not recommended for beginning surgeons, as this might be technically difficult. As such, in each individual patient, the amount of effect desired should be weighed against the experience of the surgeon and the potential ease of the surgery when deciding which parameters should be used. Although most patients in our study achieved their goal of becoming contact lens-tolerant after surgery, it is interesting that INTACS appears to work better in patients with mild disease than more severe disease even in the absence of central corneal

scarring. Our analysis of a subgroup of patients who only had one single INTACS inserted versus the group that had two INTACS inserted showed no statistically significant differences for all outcome measures between the two groups (Table 4). This suggests that a single INTACS is just as effective as two INTACS in mild to moderate asymmetric cones.

Considering that INTACS on average reduce central K readings by approximately 3.0 D and reports in the literature suggest that patients who experience contact lens fitting difficulties have K readings >55.0 D,<sup>2</sup> we recommend that INTACS using the current technology be inserted in patients who have K readings  $\leq 57.0$  D. Other contraindications for INTACS using this technology are patients with corneal thickness <450  $\mu\text{m}$  at the 7-mm optical zone, patients with central corneal scarring, and patients who expect to become independent of spectacles or contact lenses after this procedure.

It is interesting to note that in our study using the IntraLase, we were able to demonstrate similar visual outcomes to the mechanical studies performed by Colin et al<sup>6</sup> and Siganos et al<sup>7</sup> despite the fact that in their studies they were able to use the 0.45-mm segments, which potentially produce more effect. The maximum diameter INTACS available for use in the United States is 0.35 mm. We believe our good results might be due to the accurate depth of the channel creation, which is 400  $\mu\text{m}$ . The consistency of depth, the uniformity of the cut, and the minimal trauma induced when creating the en-



try cut might also be contributing factors. Future studies may provide insight as to why this occurs. Our study is not directly comparable to the previously reported mechanical studies<sup>6,7</sup> because we are comparing 6-month data to 12-month data; however, Colin et al<sup>6</sup> reported that their patients improved over time, which suggests our results are even more encouraging.

The overall goal of our study was to flatten the corneas maximally so as to improve contact lens-tolerance, and as such, we used symmetric 0.35-mm segments in most patients. The study by Colin et al<sup>5</sup> and our one case example of a patient with mild disease suggest that asymmetric segments might have a significant effect in reducing keratometric astigmatism.<sup>5</sup> To achieve uniform results and to avoid neovascularization of the wound from contact lens wear, all incisions were made temporally, and as such, we did not try to determine the effect of the entry wound location on the refractive astigmatism or overall result. This will be the subject of future studies.

INTACS insertion using the IntraLase femtosecond laser is a simple procedure, which is likely to be embraced by surgeons and patients who wish to avoid or delay corneal transplants. The present study suggests that outcomes in the femtosecond laser group are comparable to outcomes using the mechanical spreader. This technique, in its infancy, has the potential for significant improvement once the optimal nomogram for channel size, depth, and entry incision has been determined. In the future, this procedure could be combined with customized photorefractive keratectomy (PRK) (in select patients with adequate corneal thickness) to achieve improved UCVA in patients with keratoconus—INTACS to reduce the higher order aberrations

to improve BSCVA and PRK to correct the residual refractive error. The potential for such treatment is currently the subject of investigation at our institution.

## REFERENCES

1. Rabinowitz YS. Keratoconus. *Surv Ophthalmol*. 1998;42:297-319.
2. Smiddy WE, Hamburg TR, Karcher GP, Stark WJ. Keratoconus. Contact lenses or keratoplasty? *Ophthalmology*. 1988;95:487-492.
3. Zadok D, Schwartz S, Marcovich A, Bakana Y, Morad Y, Eting E, Avni I. Penetrating keratoplasty for keratoconus. Long-term results. *Cornea*. 2005;24:959-961.
4. Linebarger EJ, Song D, Ruckhofer J, Schanzlin DJ. Intacs: the intrastromal corneal ring. *Int Ophthalmol Clin*. 2000;40:199-208.
5. Colin J, Cochener B, Savary G, Malet F. Correcting keratoconus with intracorneal rings. *J Cataract Refract Surg*. 2000;26:1117-1122.
6. Colin J, Cochener B, Savary G, Malet F, Holmes-Higgin D. INTACS inserts for treating keratoconus: one-year results. *Ophthalmology*. 2001;108:1409-1414.
7. Siganos CS, Kymionis GD, Kartakis N, Theodorakis MA, Astyrakakis N, Pallikaris IG. Management of keratoconus with Intacs. *Am J Ophthalmol*. 2003;135:64-70.
8. Boxer Wachler BS, Christie JP, Chandra NS, Chou B, Korn T, Nepomuceno R. Intacs for keratoconus. *Ophthalmology*. 2003;110:1031-1040.
9. Hellstedt T, Makela J, Uusitalo R, Emre S, Uusitalo R. Treating keratoconus with Intacs corneal ring segments. *J Refract Surg*. 2005;21:236-246.
10. Alio JL, Artola A, Hassanein A, Haroun H, Galal A. One or 2 Intacs segments for the correction of keratoconus. *J Cataract Refract Surg*. 2005;31:943-953.
11. Levinger S, Pokroy R. Keratoconus managed with Intacs: one year results. *Arch Ophthalmol*. 2005;123:1308-1314.
12. Sugar A. Ultrafast (femtosecond) laser refractive surgery. *Curr Opin Ophthalmol*. 2002;13:246-249.
13. Ruckhofer J, Stoiber J, Alzner E, Grabner G. Intrastromal corneal ring segments (ICRS, Keravision ring, Intacs) clinical outcome after 2 years [German]. *Klin Monatsbl Augenheilkd*. 2000;216:133-142.