

Surgical Treatment of Advanced Pellucid Marginal Degeneration

Karim Rasheed, MD, MSc,¹ Yaron S. Rabinowitz, MD^{1,2}

Purpose: To determine the efficacy of simultaneous peripheral crescentic lamellar keratoplasty (LK) and central penetrating keratoplasty (PK) for advanced pellucid marginal degeneration (PMD).

Design: Retrospective, noncomparative, interventional case series.

Participants: Five patients with advanced PMD.

Method: Simultaneous peripheral crescentic LK and central PK followed by selective suture removal and astigmatic keratotomy in the postoperative period.

Main Outcome Measures: These included interval of time required for visual rehabilitation, best spectacle-corrected visual acuity achieved, and amount of corneal astigmatism, as measured by videokeratography. Measuring the change in corneal astigmatism by videokeratography over the subsequent follow-up period after spectacle correction had been prescribed assessed stability of the achieved refraction.

Results: Visual acuity results were 20/40 in three eyes, 20/80 in one eye, and 20/400 in one eye. The latter two had decreased acuity from posterior subcapsular cataract formation, which may have been caused by topical steroid use. The time required for visual rehabilitation ranged from 5.13 to 10.93 (mean, 9.92) months, and the amount of corneal astigmatism at the end of this period ranged from 0.3 diopters (D) to 5.3 D. A tendency for an increase in "with the rule astigmatism" after the rehabilitation period was noted. Two patients had elevations of intraocular pressure that responded to reduction in topical steroid dose.

Conclusions: The short-term results with this technique are excellent in that it provides early and stable visual rehabilitation in patients with advanced PMD. Low to moderate levels of postkeratoplasty astigmatism were achieved in all the eyes treated. The usual tendency of an increase in "against the rule astigmatism" that occurs when PK alone is done for PMD was eliminated. *Ophthalmology* 2000;107:1836-1840 © 2000 by the American Academy of Ophthalmology.

Advanced pellucid marginal degeneration (PMD) causes severe deterioration in vision. Rigid contact lenses, which are of benefit in mild disease, fail when the disease becomes severe.¹⁻⁴ Surgery is often the treatment of last resort, and a number of surgical procedures have been tried. These include crescentic wedge resection, crescentic lamellar keratoplasty, central penetrating keratoplasty (PK), oversized central PK, inferiorly decentered PK, epikeratophakia, and thermokeratoplasty.⁵⁻¹³ Except for epikeratophakia and thermokeratoplasty, different surgeons are still using many of the preceding procedures to treat advanced PMD. The fact that so many different procedures are still used implies that the optimum surgical treatment has yet to be devised.

We present herein the results of a modified procedure in which an inferior crescentic lamellar keratoplasty (LK) was combined with a central penetrating keratoplasty. Both of these procedures are done in the same sitting.

Methods

The medical records of all patients with advanced PMD who had undergone this procedure in our practice over a period of 4 years were examined. Preoperative and postoperative best-corrected spectacle visual acuities, corneal topography maps, and other relevant clinical information were extracted and analyzed. A fellowship-trained cornea specialist (YSR) carried out the transplant procedures and follow-up examinations except in one case, in which the referring ophthalmologist, who also was a fellowship-trained cornea specialist, carried out late follow-up. Follow-up data were extracted at the time spectacle correction was first prescribed after surgery and at the time of the patients' last follow-up visit.

Surgical Technique

All patients received a retrobulbar and modified Van Lint facial nerve block. After preparing and draping the eye, a 7/0 Vicryl suture on a cutting needle was passed through a partial thickness of the superior cornea. The eye was rotated upward by traction on the suture, which was then fixed with a clamp to the drapes.

Using calipers, a mark was made 1 mm centripetal to the inferior limbus at the 6 o'clock position. The inferior edge of a

Originally received: September 16, 1999.

Accepted: May 18, 2000.

Manuscript no. 99641.

¹ Cornea-Genetic Eye Institute, Burns and Allen Research Institute, Cedars Sinai Medical Center and Department of Ophthalmology, UCLA School of Medicine, Los Angeles, California.

² Departments of Medicine and Pediatrics, UCLA School of Medicine, Los Angeles, California.

Presented in part at the American Academy of Ophthalmology annual meeting, San Francisco, California, October 1997.

Supported by NIH Grant EY09052 and The Eye Birth Defects Research Foundation, Inc., Los Angeles, California.

Reprint requests to Yaron S. Rabinowitz, MD, Cornea-Genetic Eye Institute, Cedars-Sinai Medical Center, Mark Goodson Building, Suite 1102, 444 South San Vicente Boulevard, Los Angeles, CA 90048.

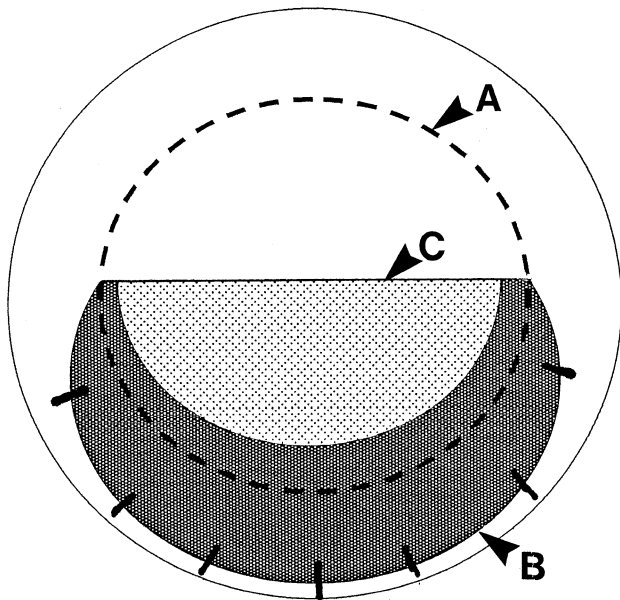


Figure 1. Line drawing of the cornea showing the lamellar graft in situ. Arrow "B" points to the inferior edge of the lamellar transplant, and arrow "C" points to the superior edge of the lamellar dissection. Arrow "A" points to the position where the suction trephine will be applied.

10-mm disposable Weck trephine (S. Med, Jacksonville, Florida) was then aligned with this mark, and a 10-mm imprint on the cornea was made through the epithelium without actually penetrating the cornea. A ruler was then used to draw a horizontal line in the center of the cornea extending from the 3 o'clock to the 9 o'clock position. The semicircular area of host tissue within the borders of the trephine line and below the horizontal midline was dissected away with a super sharp blade at approximately 50% depth, and a clean bed was prepared.

The donor cornea was then trephined with a 7.5-mm Pharmacia trephine (Pharmacia & Upjohn, Groningen, Netherlands) from the endothelial side and placed in a moist chamber. A 10-mm Weck trephine was then used to trephine the residual donor cornea from the epithelial side to 50% depth. The trephine was positioned with one edge at the limbus of the host cornea such that a crescent of maximum possible width was fashioned. Using a super sharp blade, a crescentic lamellar piece of donor cornea was then dissected from the donor button. This lamellar piece of donor cornea was then trimmed to fit into the prepared host bed and sutured in place with multiple interrupted 10/0 nylon sutures. The center of the host cornea was marked, and a 7-mm Baron Hessburg Trephine (JEO Med, St Louis, Missouri) was then centered on the host cornea. This trephined the host cornea superiorly and the area inferiorly, which had now been augmented with the crescentic lamellar graft. Suction was applied and the trephine turned until fluid leakage was noticed. Figure 1 is a diagrammatic representation of the lamellar graft in situ. Arrow "B" points to the inferior edge of the lamellar transplant, arrow "C" points to the superior edge of the lamellar dissection, and arrow "A" points to the position where the suction trephine was applied. The host tissue was then removed in the standard fashion with corneal scissors. The 7.5-mm donor button was then sutured into the host, with the inferior sutures passing through both host and sutured in lamellar graft tissue. Figure 2 illustrates the positions of the central penetrating keratoplasty (PK) (arrow A) and the inferior lamellar keratoplasty (LK) (arrow B). The placement of the interrupted and continuous 10/0 nylon sutures is also illustrated. Figure 3 is a

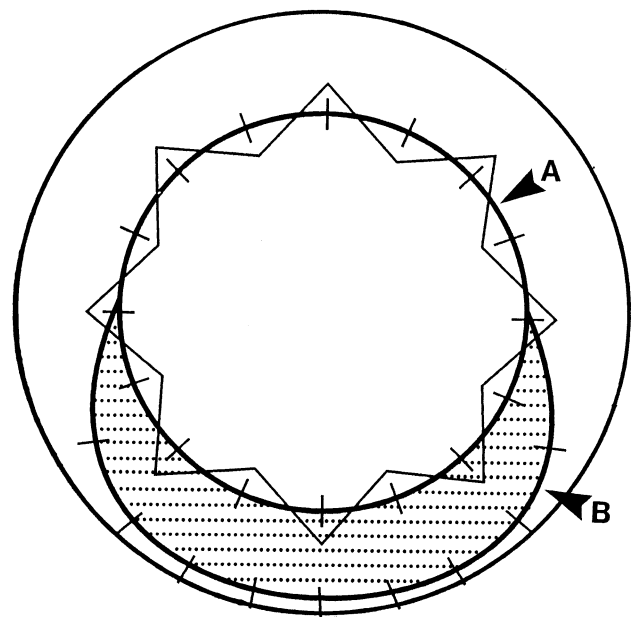


Figure 2. Line drawing of the cornea illustrating the central penetrating keratoplasty (arrow A) and the inferior lamellar keratoplasty (arrow B). The placement of the interrupted and continuous 10/0 nylon sutures is also illustrated.

photograph of the whole cornea of one of these patients taken once all sutures had been removed. Again, arrow A and arrow B mark the edges of the central PK and the inferior LK. Figure 4 is a magnified view of the inferior LK, the edge of which is marked with the arrow.

Sutures to the lamellar graft were removed completely approximately 2 months from the date of the procedure, and the sutures holding the central penetrating graft were removed selectively, guided by videokeratography and refraction, starting at 3 months from the date of surgical procedure. If the amount of astigmatism was judged to be so severe as to not be tolerable in a spectacle prescription, astigmatic keratotomy and/or compression sutures were also used.^{12,13} Visual rehabilitation was considered complete when an acceptable refraction was achieved and the patient was prescribed the spectacle correction. This duration was used as one of the end points in this study.

Statistical Analysis

Stability of achieved refraction was assessed by comparing the degree of corneal astigmatism present immediately after the rehabilitation period with the astigmatism present at the end of the follow-up period. For this purpose, the keratometry readings of the steepest and the flattest orthogonal axes as measured by videokeratography were used. The magnitude of the corneal astigmatism vector was calculated by subtracting the steepest Sim K from the flattest Sim K measurement. This corneal astigmatism vector was decomposed into the rectangular *x* and *y* axis components with simple trigonometry. The late astigmatism vectors were subtracted from the early astigmatism vectors to determine the change in astigmatism over the study period. The change in astigmatism was divided by the elapsed time to derive the rate of change of astigmatism in each meridian. The mean of these mean rates of change was derived to reflect the rate of change of astigmatism of the entire group.

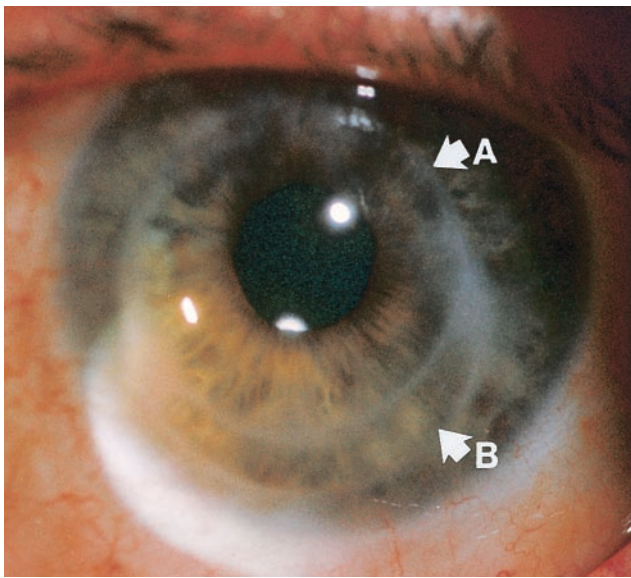


Figure 3. Slit-lamp photograph of an operated eye 17 months after surgery illustrating the central penetrating keratoplasty (arrow A) and the crescentic inferior lamellar keratoplasty (arrow B).

Results

Five patients were identified, each of whom had one eye treated for advanced PMD with this technique. They were all adult men with ages ranging from 34 to 49 years. One was African American, and four were Caucasian. Three months after the surgery, videokeratography-guided selective suture removal was begun. In all eyes in the wound astigmatic keratotomy was also required, and in one eye compression sutures were required. The timing of the astigmatic keratotomies varied. Spectacles were not prescribed until at least 1 month after the last refractive manipulation. No episodes of graft rejection were noted during the follow-up period. Table 1 shows the postoperative best spectacle-corrected visual acuity results and the time required for visual rehabilitation for each of these patients. Figure 3 is a slit-lamp photograph of the operated eye of patient 1. The mean duration before spectacle correction was prescribed was 9.92 months (range, 5.13–20.93 months). In patient 3, the rehabilitation period was prolonged because he missed a number of appointments. In patients 3 and 4, the postoperative course was complicated by

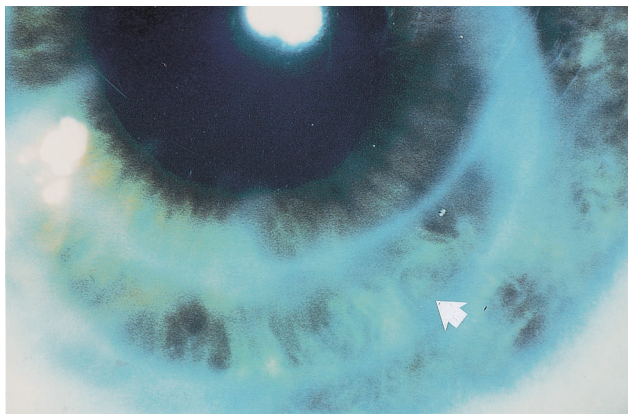


Figure 4. High-magnification slit-lamp photograph of the inferior cornea illustrating the lamellar keratoplasty. The inferior edge of the graft is marked by the arrow.

increases in intraocular pressure and the development of posterior subcapsular cataracts. These phenomena we presumed were related to topical steroid use. The intraocular pressure elevations were successfully controlled by the use of topical antiglaucoma medications, and in both of these patients the intraocular pressure fell as the topical steroid eyedrops were reduced.

Table 2 presents the analysis evaluating stability of achieved refraction. x_1 and y_1 are the x and y axis components of the corneal astigmatism vector at the end of the rehabilitation period, and x_2 and y_2 are the x and y axis components of the corneal astigmatism vector at the time of the last follow-up appointment. The small positive change in the mean y -axis component represents the slight increase in the “with the rule” astigmatism observed in four of the five eyes. The magnitude of this gradual “with the rule” trend was 0.32 D per year.

Discussion

PMD is a progressive, noninflammatory peripheral corneal thinning disorder characterized by a peripheral band of thinning of the inferior cornea from the 4-o’clock to the 8-o’clock position accompanied by 1 to 2 mm of normal cornea between the limbus and the area of thinning.^{1–4} The condition is rare; however, there may be a considerable underestimation of the incidence because patients with this condition are often misdiagnosed as having keratoconus.² As in keratoconus, this disorder is progressive, with advanced cases exhibiting marked corneal protrusion that makes differentiation from keratoconus difficult.^{1–4}

Spectacle correction usually fails very early in the course of this disease as the degree of irregular astigmatism increases. In early to moderate cases, rigid contact lenses are beneficial in providing visual rehabilitation. In patients who are contact lens intolerant or in whom the ectasia is of such a degree that rigid contact lenses do not provide adequate visual acuity, surgery may have to be considered. A number of surgical procedures have been performed in an attempt to provide visual rehabilitation. Standard-sized PK may result in poor long-term results, because the inferior edge of the transplant has to be sutured to abnormally thin cornea, and this results in a high degree of postkeratoplasty astigmatism in the short term. In the long term continued thinning of the host cornea inferiorly produces a similar situation, which necessitates surgery in the first instance.

Large-diameter grafts have been tried in an attempt to remove as much of the affected cornea as possible; however, because of the proximity to the limbus and its blood vessels, these grafts are prone to rejection. Grafts that are deliberately decentered inferiorly also work poorly because there is a large degree of astigmatism caused by the decentering and a higher incidence of rejection, again because of proximity to the limbus.^{5,6} The results reported by Varley et al⁵ illustrate the dangers of locating the graft–host interface close to the limbus. Their series included 12 eyes that underwent PK for PMD with donor buttons that were 9.0 mm or greater. In addition, most of their transplants were decentered inferiorly to remove as much of the diseased cornea as possible. Of the 12 eyes, one failed secondary to rejection, and in the remaining 11 eyes, 7 had at least one endothelial rejection episode.⁵ Speaker et al⁶ reported their results using large transplants for the treatment of kerato-

Table 1. Visual Acuity Results

	Time Required for Visual Rehabilitation (mos)	Best Spectacle-corrected Visual Acuity after Rehabilitation Period	Best Spectacle-corrected Visual Acuity at End of Follow-up Period	Duration of Follow-up after Visual Rehabilitation (yrs)
Patient 1	5.5	20/40	20/40	1.47
Patient 2	5.1	20/40	20/40	4.83
Patient 3*	20.0	20/70	20/400	1.39
Patient 4*	8.0	20/25	20/80	1.55
Patient 5	10.9	20/40	20/40	1.55

*The visual acuity in both of these patients was reduced because of posterior subcapsular cataracts.

conus and PMD in 15 eyes. In 11 grafts sized 8.7 to 9.0 mm, one failed as a result of rejection, and of the remaining 10, 4 had at least one rejection episode. Of the four transplants that were greater than 9.5 mm in diameter, all four had at least one rejection episode each.⁶

Lamellar or full-thickness excision of a crescentic wedge of corneal tissue from the inferior cornea followed by tight suturing has been reported to reduce the corneal ectasia.⁷⁻⁹ The procedure is usually well tolerated; however, in our experience the beneficial effect has been short lived, and the thinning and ectasia recur. In addition, this procedure may be hazardous in inexperienced hands, because we have noted several instances of wound dehiscence and resulting flat anterior chambers with their attendant problems when this procedure has been attempted. MacLean et al⁹ reported their results in 10 eyes treated with corneal wedge excision for PMD. They were able to prescribe a spectacle correction in the relatively short time (range, 3-12 months) for their patients. Their results in terms of the reduction in corneal astigmatism are also impressive (range, 0.5-4.0 D). However, the refraction achieved did not seem to be stable, and there was noted a progressive increase in the against the rule astigmatism in all eyes treated. This "long-term astigmatic drift" was as much as 2.1 D per year. It is not known whether this change is due to instability of the corneal wound or whether the wedge resection causes acceleration of the underlying disease process. The results of our technique, in terms of speed of recovery and level of postkeratoplasty astigmatism, are comparable to those of MacLean and coauthors and, in our view, produce a more stable refractive result.

Crescentic LK, in which a crescentic transplant is done to reinforce the area of thinning has also been reported by Schanzlin et al,¹⁰ but the reports of this procedure have been largely anecdotal and no large series of patients in whom this procedure has been done have as yet been reported.¹¹ The combination of these two procedures is at present the favored surgical treatment. The LK is done first and is followed by the central PK. The lamellar transplant restores normal thickness to the inferior cornea and enables good edge-to-edge apposition at the time of PK, which reduces the likelihood of high postkeratoplasty astigmatism. Furthermore, the central graft that is now sutured to a normal-thickness host can be treated by selective removal of sutures guided by videokeratography and astigmatic keratotomy in the usual way to reduce any residual astigmatism. We have recently begun doing the two operations in the same sitting, with encouraging results. Doing two keratoplasty procedures necessitates the use of two separate corneas. By doing the two procedures in the same sitting, we have been able to use tissue from the same donor, potentially reducing the antigenic load. In addition, we have noted that when done as a staged procedure, the central PK is almost always needed because of residual irregular astigmatism.

Our short-term results in this small series of patients are encouraging in terms of the refractive outcome. Visual rehabilitation was rapid and the long-term, against the rule astigmatic drift was completely abolished. However, long-term follow-up is required to determine the incidence of rejection of the central penetrating graft.

Table 2. Analysis of Changes in Astigmatism Over Time in Terms of Rectangular Component Analysis

Patient	Astigmatism Present when Spectacles were First Prescribed	Rectangular Components		Astigmatism Present at Last Follow-up Visit	Rectangular Components				Interval between Measurements (yrs)	Rate of Change in Y Component Per Year (Diopters)
		X1	Y1		X2	Y2	X2-X1	Y2-Y1		
1	5.30 D × 22	4.91 D	1.99 D	3.50 D × 176	-3.49 D	0.24 D	-8.40 D	-1.75 D	1.47	-1.19 D
2	0.30 D × 94	-0.02 D	0.30 D	3.50 D × 55	2.01 D	2.87 D	2.03 D	2.57 D	4.83	0.53 D
3	3.80 D × 165	-3.67 D	0.98 D	5.54 D × 162	-5.27 D	1.71 D	-1.60 D	0.73 D	1.39	0.53 D
4	4.50 D × 145	-3.69 D	2.58 D	4.80 D × 131	-3.15 D	3.62 D	0.54 D	1.04 D	1.55	0.67 D
5	2.20 D × 97	-0.27 D	2.18 D	3.90 D × 100	-0.68 D	3.84 D	-0.41 D	1.66 D	1.55	1.07 D
Mean	NA	-0.55 D	1.54 D	NA	-2.12 D	2.46 D	NA	NA	2.16	0.32 D

D = diopter; NA = not applicable.

References

1. Krachmer JH. Pellucid marginal corneal degeneration. *Arch Ophthalmol* 1978;96:1217-21.
2. Rabinowitz YS. Keratoconus. *Surv Ophthalmol* 1998;42:297-319.
3. Maguire LJ, Klyce SD, McDonald MB, Kaufman HE. Corneal topography of pellucid marginal degeneration. *Ophthalmology* 1987;94:519-24.
4. Karabatsas CH, Cook SD. Topographic analysis in pellucid marginal corneal degeneration and keratoglobus. *Eye* 1996;10(Pt 4):451-5.
5. Varley GA, Macsai MS, Krachmer JH. The results of penetrating keratoplasty for pellucid marginal corneal degeneration. *Am J Ophthalmol* 1990;110:149-52.
6. Speaker MG, Arentsen JJ, Laibson PR. Long-term survival of large diameter penetrating keratoplasties for keratoconus and pellucid marginal degeneration. *Acta Ophthalmol Suppl* 1989;192:17-9.
7. Dubroff S. Pellucid marginal degeneration: report on corrective surgery. *J Cataract Refract Surg* 1989;15:89-93.
8. Cameron JA. Results of lamellar crescentic resection for pellucid marginal corneal degeneration. *Am J Ophthalmol* 1992;113:296-302.
9. MacLean H, Robinson LP, Wechsler AW. Long-term results of corneal wedge excision for pellucid marginal degeneration. *Eye* 1997;11(Pt 5):613-7.
10. Schanzlin DJ, Sarno EM, Robin J. Crescentic lamellar keratoplasty for pellucid marginal degeneration [letter]. *Am J Ophthalmol* 1983;96:253-4.
11. Kremer I, Sperber LT, Laibson PR. Pellucid marginal degeneration treated by lamellar and penetrating keratoplasty [letter]. *Arch Ophthalmol* 1993;111:169-70.
12. Frangieh GT, Kwitko S, McDonnell. Prospective corneal topographic analysis in surgery for post-keratoplasty astigmatism. *Arch Ophthalmol* 1991;109:506-10.
13. Rabinowitz YS, Wilson SE, Klyce SD. *Color Atlas of Corneal Topography: Interpreting Videokeratography*. New York: Igaku-Shoin, 1993; 72-7.